

Facial spasm and vertical nystagmus in a patient with Chiari type I malformation.

Espasmo facial e nistagmo vertical em paciente com malformação de Chiari tipo 1.

Luiz Felipe Vasconcellos, MD, PhD. 

Institute of Neurology Deolindo Couto- Federal University of Rio de Janeiro- Rio de Janeiro, RJ, Brazil

ABSTRACT

Background: Hemifacial spasm (HFS) is a movement disorder characterized by involuntary contractions of the muscles innervated by the facial nerve. Although most cases are caused by a vascular compression of the facial nerve (VII), others secondary causes should be considered when atypical neurological signs are present.

Case report: 64-year-old man with long-standing bilateral facial spasm associated with vertical nystagmus. Brain magnetic resonance imaging revealed Chiari type I malformation with compression of the VII and VIII cranial nerve roots.

Conclusion: This case highlights the importance of a detailed neurological examination in patients with hemifacial spasm, as associated signs may indicate underlying structural abnormalities that warrant neuroimaging. Recognizing such cases may help detect underlying causes and inform treatment decisions.

Keywords: Chiari Malformation; Facial Nerve; Hemifacial Spasm; Nystagmus, Pathologic; Magnetic Resonance Imaging.

RESUMO

Introdução: O espasmo hemifacial (EHF) é um distúrbio do movimento caracterizado por contrações involuntárias dos músculos inervados pelo nervo facial. Embora a maioria dos casos seja idiopática, devem ser consideradas causas secundárias quando estiverem presentes sinais neurológicos atípicos.

Relato de caso: Descreve-se um homem de 64 anos com espasmo facial bilateral de longa data que, ao exame, apresentava também nistagmo vertical. A ressonância magnética cerebral revelou malformação de Chiari tipo I com compressão das raízes dos nervos cranianos VII e VIII.

Conclusão: Este caso destaca a importância de um exame neurológico completo em pacientes com espasmo hemifacial, pois sinais associados podem indicar anomalias estruturais subjacentes, o que justifica a solicitação de neuroimagem. Reconhecer tais casos pode ajudar a identificar causas subjacentes e a orientar decisões terapêuticas.

Palavras-chave: Espasmo Hemifacial; Malformação de Chiari; Nistagmo patológico; Nervo Facial; Ressonância Magnética.

ARTICLE INFO

DOI: <https://doi.org/10.46979/rbn.v61i4.71940>

Corresponding Author:

Luiz Felipe Vasconcellos.
Email: luizneuro@terra.com.br

Conflict of Interest: The author declare that there is no conflict of interest associated with the conduct of this study.

Funding: This research did not receive any funding.

INTRODUCTION

Hemifacial spasm (HFS) is characterized by involuntary, irregular contractions of muscles on one side of the face and from a phenomenological standpoint, it is classified as peripheral myoclonus¹. It is noteworthy for being one of the movement disorders that persist during sleep. Botulinum toxin injections are considered the treatment of choice, while microvascular decompression is reserved for selected refractory cases².

Chiari malformations comprise a spectrum of posterior fossa abnormalities characterized by downward displacement of cerebellar structures through the foramen magnum. They could be associated with other structural abnormalities depending on the type. The most common form in adults is Chiari malformation type I (CM-I), defined by isolated tonsillar herniation, which may be associated with headache, limb numbness or weakness, ataxia, cranial nerve impairment, or nystagmus. Chiari malformation type II involves descent of the cerebellar vermis and fourth ventricle and is typically associated with open myelomeningocele. Types III, IV, and V are rare, severe forms that include occipital encephalocele and varying degrees of cerebellar hypoplasia, predominantly affecting infants and children³.

The association between CM I and HFS is rarely described in the literature, with few cases reported^{4,5}. This case report describes a patient with bilateral HFS and vertical nystagmus related to CM-I, aiming to raise awareness of this uncommon presentation.

CASE REPORT

A 64-year-old man presented with involuntary facial spasms that began on the right side ten years prior and progressively involved the left side. Neurological examination revealed bilateral facial spasm and vertical nystagmus, with no additional abnormalities.

Brain MRI showed CM-I malformation. The cerebellar tonsils herniated through the foramen magnum and pressed on the VII and VIII cranial nerve roots (Figure 1).

The neurosurgery service evaluated the patient and did not recommend surgical intervention. The patient was treated with botulinum toxin injections, resulting in significant symptomatic improvement.

DISCUSSION

Isolated hemifacial spasm does not routinely require neuroimaging, as the standard treatment remains botulinum toxin therapy. However, the presence of additional neurological signs, such as nystagmus, warrants further investigation².

In the present case, both facial spasm and vertical nystagmus were attributed to compression of the facial and vestibulocochlear nerves, respectively, caused by downward displacement of the brainstem associated with CM-I⁵. This reinforces the importance of careful neurological examination to guide appropriate use of diagnostic imaging and avoid unnecessary investigations.

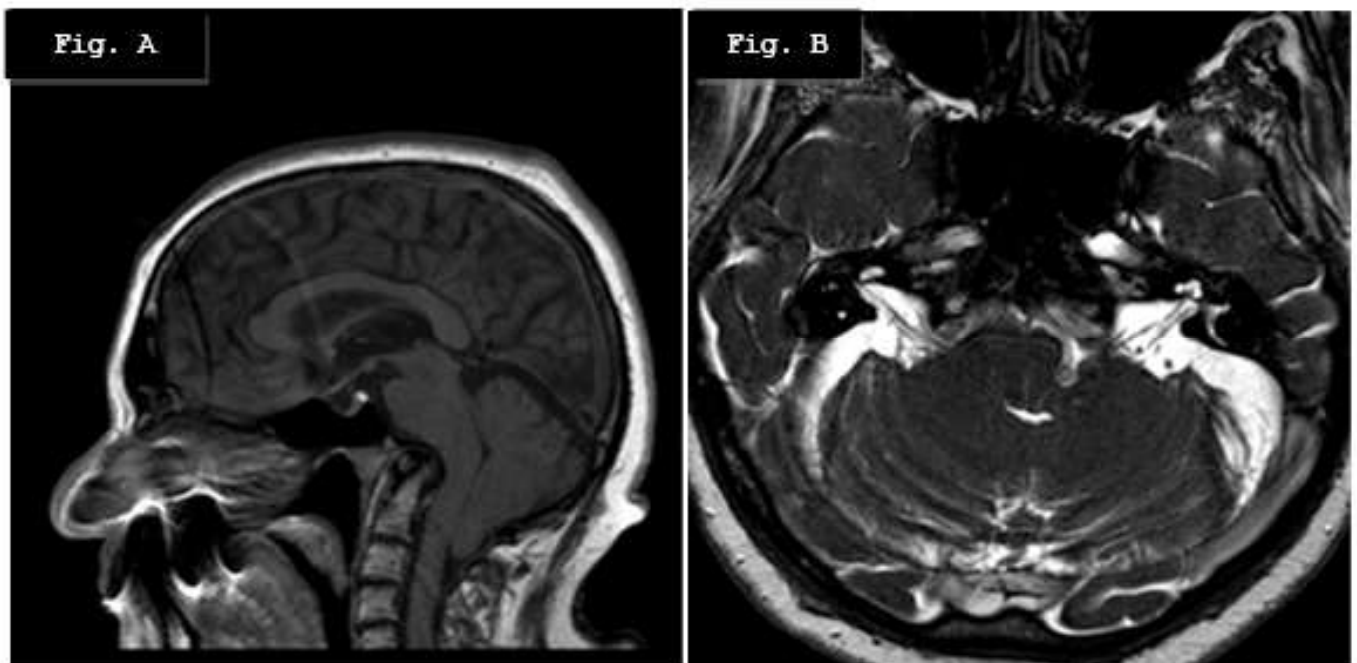


Figure 1. Brain MRI.

A. T1-weighted sagittal imaging: herniation of the cerebellar tonsils through the foramen magnum, defining Chiari type I malformation.

B. T2-weighted axial imaging: deletion of the pre-pontine cistern, fourth ventricle collapse, and compression of the roots of the VII and VIII right cranial nerves by the C2 vertebra.

CONCLUSION

This case underscores the relevance of comprehensive neurological assessment in patients with hemifacial spasm. The identification of associated neurological signs may reveal underlying structural abnormalities and directly influence diagnostic and therapeutic decision-making.

REFERENCES

1. Dijk JM, Tijssen MA. Management of patients with myoclonus: available therapies and the need for an evidence-based approach. *Lancet Neurol*. 2010 Oct;9(10):1028-36. doi: 10.1016/S1474-4422(10)70193-9. PMID: 20864054.
2. Chaudhry N, Srivastava A, Joshi L. Hemifacial spasm: The past, present and future. *J Neurol Sci*. 2015 Sep 15;356(1-2):27-31. doi: 10.1016/j.jns.2015.06.032. Epub 2015 Jun 16. PMID: 26111430.
3. Friedlander RM. Congenital and Acquired Chiari Syndrome. *N Engl J Med*. 2024 Jun 20;390(23):2191-2198. doi: 10.1056/NEJMra2308055. PMID: 38899696.
4. Felício AC, Godeiro-Junior Cde O, Borges V, Silva SM, Ferraz HB. Hemifacial spasm in a patient with neurofibromatosis and Chiari malformation: a unique case association. *Arq Neuropsiquiatr*. 2007 Sep;65(3B):855-7. doi: 10.1590/s0004-282x2007000500026. PMID: 17952297.
5. Colpan ME, Sekerci Z. Chiari type I malformation presenting as hemifacial spasm: case report. *Neurosurgery*. 2005 Aug;57(2):E371; discussion E371. doi: 10.1227/01.neu.0000166688.69081.8b. PMID: 16094141.